

The evolution of care

Why 'perioscopy' could change the way you view your patients. by Judy Carroll, RDH

TAKE-AWAY

■ The future is now

Minimally invasive technology is the future of dentistry. Perioscopy is a way to participate now.

■ We can do better

Dental endoscopes raise the bar for detecting decay early and treating it thoroughly.

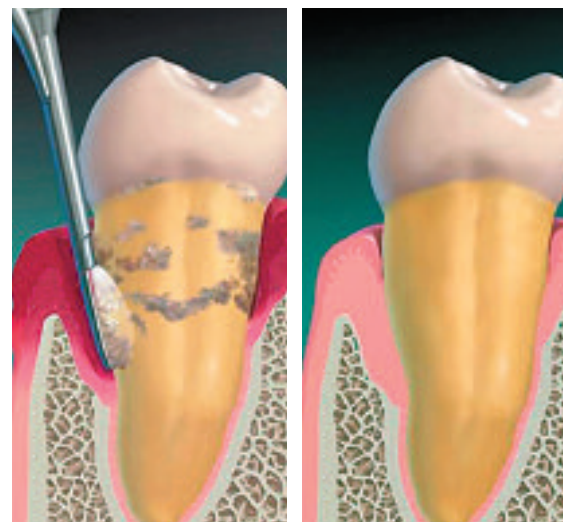Six years ago, an innovative fiber optic dental technology emerged that both challenged and changed the foundational knowledge, philosophy, and clinical possibilities within the dental hygiene profession. Finally, fiber optic dental technology had come to fruition.

Dental endoscope technology, or perioscopy, has the power to redefine and reshape the very future of the profession. A true visual understanding of the subgingival world is, in and of itself, priceless for the dental hygienist. Yet it may also hold the key to a major paradigm shift in the non-surgical clinical possibilities for the dental hygiene profession, including non-surgical bone regeneration. This article will explore the evolution, significance, and exciting future of perioscopy.

The DentalView DV2 Perioscopy System allows the clinician to see clearly into a shallow or deep sulcus using a brightly illuminated fiber optic lens that provides 24X to 48X magnification. The image is then projected live onto a high-resolution flat screen color monitor for real time imaging. At just 0.99 mm in diameter, this tiny flexible fiber is not only small, but powerful.

Special instruments called explorer probes are used to guide the fiber into the sulcus. The image itself is fluid, as water is flushed through the fiber sheath and into the sulcus for a clear view. With a new magnified view of the roots, sulcular tissue, enamel, attachment fibers, and bone, our understanding of those areas magnified as well.

Undetected burnished subgingival calculus containing pathogenic bacteria is lurking everywhere, wreaking havoc on the sulcular epithelium, cementum, PDL fibers, and alveolar bone. These burnished "condos" for bacteria go unnoticed for years, as chronic and/or acute infection often ensues. Well-intentioned clinicians may use everything from blind root planing and lasers, to LAAs (locally applied anti-



The first image illustrates the large amount of subgingival calculus that can be left behind following "blind" root planing. Because of this, chronic disease persists. The second image demonstrates a post-perioscopy tissue response; health is restored non-surgically.

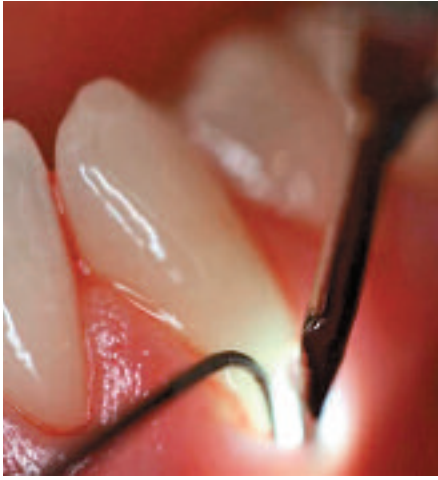microbials), repetitive ultrasonic therapy, beefing up home care, or chemotherapeutics in an attempt to control these infections.

Research on the effectiveness of blind root planing shows it to be lacking in many ways – following blind root planing, as much as 50% of the subgingival calculus beyond a depth of 4 mm remains.^{1,2,3,4} Despite this, blind root planing remains the standard.

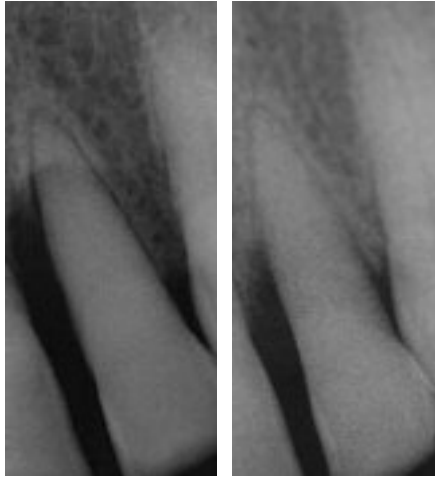
A CLEAR VIEW

The first techniques used in perioscopy were a bit crude and very slow. Trying to understand the images provided by the new sub-gingival microscope was comparable to being an explorer in uncharted territory beneath the ocean's surface. These live subgingival images clearly displayed the "ugly" objective truth about the reality of the sulcus and our need for improved clinical skills. The ability to actually see subgingival burnished and microscopic calculus now presented the overwhelming and incredible new challenge of removing it efficiently and accurately.

Today, a procedure known as "two-handed perioscopy" has become a popular technique for experienced perioscopy clinicians. The "look and locate, remove and reevaluate" approach to finding calculus has been replaced by the "remove while viewing" approach. Gone are the days of spending two hours a quadrant while employing a full tray of instruments! With the advanced two-handed ultrasonic and perioscopy technique, a single tooth can be treated in



Here we see the two-handed perioscopy technique used on an inflamed, recessed site. This approach allows users to view the debridement procedure as they perform it. Learning and adapting this skill does require practice.



The first image is a "before perioscopy" x-ray of a patient's No. 10 tooth with 10 mm pockets and Class III mobility. The second image, taken nine months later, shows a healthier tooth probing within normal limits and with no mobility.

just minutes, and an entire quadrant in less than an hour.

Perioscopy has evolved into a highly efficient full mouth procedure for non-invasive, thorough microscopic root debridement. This skill does not come easily, nor does it come overnight, but it **does** come with practice and determination.

DEFINITIVE DIAGNOSIS OF DECAY

Even though the biofilm thriving in and around burnished calculus is enough to perpetuate chronic and/or acute periodontal infection, another source of continuous biofilm infection may be from undetected decay. Root

Crescent 1/2 H

Use **XXX** on card or at www.dentalproducts.net

Treating decay early is a worthwhile addition to any office protocol. A routine cleaning utilizing a perioscope raises the bar and resets the standard for definitive, preventive oral healthcare.

decay, interproximal decay, and recurrent decay around failing restorations, faulty crown margins and root fractures, all contribute to periodontal infection. With the routine use of an endoscope, the user discovers that our current diagnostic methodologies only provide so much information, and cannot be trusted entirely. Undiagnosed decay may be the true etiology of scores of unresolved periodontal infections.

This eye-opening truth is a great opportunity to deliver a higher level of care. Finding and treating decay early is a worthwhile addition to any office protocol. A routine examination and/or cleaning utilizing a perioscope raises the bar and resets the standard for definitive, preventive oral healthcare.

UNSEEN VALUE

A dental endoscope is one of the most valuable tools available to the hygienist, and should be used as routinely as probing and/or x-rays. When time, practice, and dedication are a priority, the perioscopy clinician becomes "enlightened" in his or her clinical expertise. Clinical knowledge and skill elevate to an intuitive realm well beyond what could be achieved in the absence of perioscopy. While the patient benefits enormously from this newly developed competence, the clinician's place in the professional world becomes increasingly rewarding in many, ways, including increased job satisfaction, new potential income, and a renewed passion for their career.

Perioscopy alone is a substantial technological breakthrough for the dental hygiene pro-

fession, but what happens if we combine perioscopy with another leading edge technology such as enamel matrix proteins? These bioactive molecules can easily be placed with proper technique during perioscopy to regenerate bone non-surgically. Made from the developing teeth of pigs, this protein stimulates the regeneration of cementum, PDL, and alveolar bone. While this is not yet mainstream, it certainly has merit and potential, and could profoundly change the future of the dental hygienist's role in non-surgical periodontics.

LOOKING AHEAD

Major barriers for *using* a dental endoscope efficiently have been overcome, so the inevitable questions become: *why* perform perioscopy, and *who* benefits?

To answer this, we need only look at the declining periodontal health of the patients we have seemingly exhausted everything within our "scope of practice" and expertise to help. Or, how about the patient who does everything right and still has chronic inflammation with declining attached gingiva? What about the patient with chronic or acute periodontitis who refuses to see a periodontist for fear of surgery? How about the patient for whom flap or osseous surgery is contraindicated? Even more importantly, now that periodontal disease has been connected to so many other potentially harmful or even fatal diseases, isn't it time to look for more effective treatment options we can reasonably employ to eliminate and/or prevent infection entirely?

Perioscopy is a quantum leap for the dental

hygiene profession, and while availability may be limited, it is here to stay. Dental endoscopy technology will continue to evolve, and perioscopy will hopefully do for dentistry what medical endoscopes have so impressively done for medicine. Minimally invasive science and technology are the future and subgingival microscopy is a natural technological progression that just makes sense. [ml](#)

Judy Carroll, RDH, is a writer, speaker, consultant and clinical perioscopy instructor. Also, she is the founder of PerioPeak Innovations, providing non-surgical approach solutions for clients with periodontal disease. She also shares her innovative clinical techniques in perioscopy through privately held "hands-on" courses, and is available by appointment for consulting/speaking engagements. For more information, visit www.periopeak.com.

1. Stambaugh, R.V. et al: The Limits of Subgingival Scaling Int. J. Perio. Rest. Dent. 1981; 5:31.

2. Rabbani, G. M., Ash, M. M., and Caffesse, R. G.: The Effectiveness of Subgingival Scaling and Root Planing in Calculus Removal J. Periodontal 1981;52:119.

3. Fleischer, H. et al. Scaling and Root Planing Efficacy in Multirrooted Teeth. J Perio 1989;60:402-9.

4. Sherman, PR. et al. The Effectiveness of Subgingival Scaling and Root Planing. I. Clinical detection of residual calculus. J. Perio 1990;61:3-8.

In the December issue... Recognizing perioscopy as a step in the future of periodontology, next month we will be featuring a special piece in which Laura Mallery, RDH, MSDHED, takes us a peek into a typical exam using dental endoscopy technology.